

# Hip Preservation in Sequelae of Septic Arthritis in the Newborn, Case Report

Mauricio Vergara<sup>1\*</sup>, José Pablo Riquelme<sup>2</sup>, Alejandra Rivadeneira<sup>3</sup> and María Catalina Gaggero<sup>3</sup>

<sup>1</sup> Head of Trauma and Orthopedics Pediatric Surgery Department, Hospital Dr. Exequiel Gonzales Cortés, University Santiago de Chile, Chile.

<sup>2</sup> Head of Research Department of Trauma and Pediatric Orthopedics Surgery Department, Hospital Dr. Exequiel Gonzales Cortés, University Santiago de Chile, Chile.

<sup>3</sup> Resident of Trauma and Pediatric Orthopedics Surgery, Hospital Dr. Exequiel Gonzales Cortés, University Santiago de Chile, Chile.

**\*Corresponding Author:** Mauricio Vergara, Head of the Trauma and Orthopedics Pediatric Surgery Department, Hospital Dr. Exequiel Gonzales Cortés, University Santiago de Chile, Chile.

DOI: <https://doi.org/10.58624/SVOAOR.2024.04.071>

Received: May 11, 2024 Published: June XX, 2024

## Abstract

Septic arthritis of the hip in newborn may cause severe sequelae that has a negative impact on daily living activities. We present a patient with septic arthritis of the right hip in the newborn period (NB) classified as type IV-A according to Choi, in order to increase coverage to prevent progression of subluxation and improve joint containment and stability, a Dega-type acetabuloplasty was performed at the age of 5 years old. The patient lost follow-up for five years, she consulted again and after clinical and radiological evaluation a pelvic support osteotomy was planned and performed at the age of 15 for hip preservation. We share the postoperative outcomes observed in a rare case with complications, following hip preservation surgery, with the long-term follow-up until 22 years old. This case shows that maintaining a stable hip between the femoral epiphysis and the acetabulum, allows to reduce complications, like lower limb length discrepancy (LLD) and worsening of the activity of daily living (ADL) and postponing, or preventing hip replacement at younger ages.

**Keywords:** Septic; Arthritis; Infection; Dega, Hip; Preservation.

## Introduction

Septic arthritis is an acute joint inflammatory process, produced by the invasion and multiplication of pathogenic microorganisms. The most common agent is Staphylococcus, however, in newborns and infants there is a higher incidence of Streptococcus Pyogenes, Streptococcus Pneumoniae and occasionally, gram-negative bacilli such as Salmonella sp., Escherichia coli and Kingella Kingae has also been described as responsible for osteoarticular infections in children under 3 years of age. The prevalence of the different etiological agents has evolved over time and varies between different countries. An increase in methicillin-resistant S. Aureus (MRSA) have also been observed in countries such as the United States of America (USA), some countries in Europe and Latin America [1,2].

This microorganism reaches the joint by different routes, such as hematogenous, direct (penetrating wound to the joint, infected joint injection or surgical infection) and by contiguity, due to the extension of an osteomyelitic focus towards the joint cavity [3,4].

The joints most affected in newborns and infants are the hip and knee. It is considered a surgical emergency. Urgent evacuative arthrotomy will be aimed at avoiding cartilage destruction and preventing subsequent sequelae [5].

The sequelae of childhood septic arthritis of the hip are diverse and may include premature closure of the triradiate cartilage, acetabular dysplasia, lower limb length discrepancy (LLD), premature or asymmetric closure of the capital femoral physis, osteonecrosis of the femoral head, subluxation, dislocation, nonunion of the femoral neck and complete destruction of the femoral head and neck with devastating consequences [6].

Choi et al analyzed sequelae in a large series and classified them using a clinically useful modification of the system proposed by Hunka et al. The deformed hips were divided into 4 groups based on the nature and extent of the injury and their radiographic findings at follow-up, and each group was divided into 2 subgroups. Types III and IV sequelae are considered serious and to date, few long-term follow-up studies have been conducted on such sequelae [7].

Recommended treatment methods are as varied as the types of deformities and have not provided satisfactory long-term results. These are closed and open hip reduction, acetabular osteotomies, femoral osteotomies, epiphysiodesis of the contralateral limb, ipsilateral tibial or femoral lengthening, trochanteric surgery, arthrodesis and even total hip arthroplasty, procedures that in most cases have a high technical requirement and an uncertain prognosis for long-term function [8,9,10].

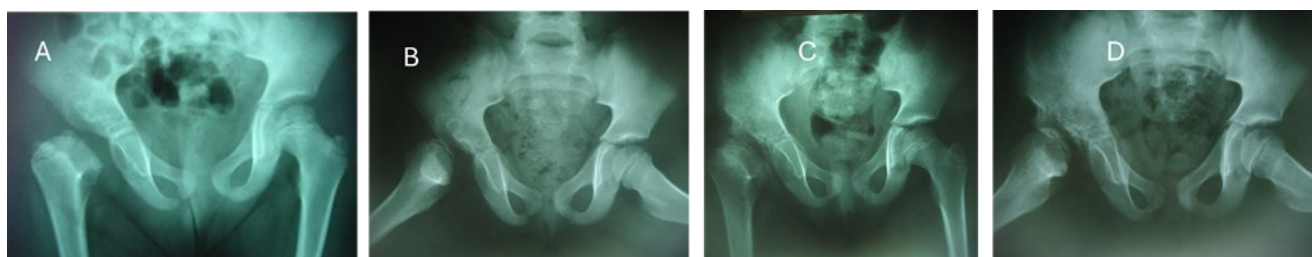The purpose of this report was to review the 22-year evolution of a clinical case of septic hip arthritis in a newborn and its treatments.

### Case Presentation

A clinical case of septic arthritis of the right hip in the newborn period (NB) is presented, classified as type IV-A according to Choi, and its long-term follow-up until 22 years of age.

Female patient who was referred to our service with a diagnosis of septic arthritis sequelae of the right hip, initially treated 12 days old with surgical treatments on three occasions, of which further history is unknown.

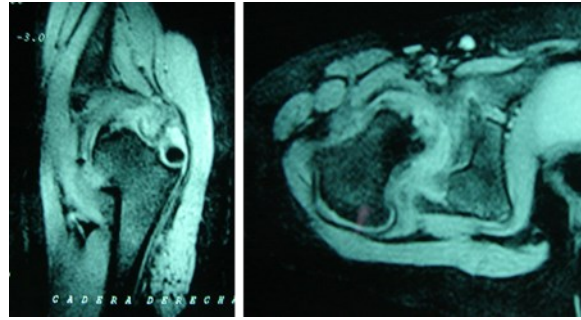
At the time of her referral, she was 4 years old, she complains of coxalgia with mild effort such as walking two blocks, but not at rest or at night, but in instrumental activities of daily living (IADL) she was unable to perform physical and recreational activities, for example, riding a bicycle. In the initial physical examination, she presented: claudication, positive Trendelenburg of the right hip, abduction 10°, internal rotation 20°, flexion 100° and a LLD of 20 mm. The simple anteroposterior hip X-ray and Lowenstein show a completely compromised femoral epiphysis, with a small anterolateral cartilaginous vestige, acetabular deficit, and subluxation (Figure 1 A and C). MRI verifies what was shown in the x-ray (Figure 2).



**Figure 1:** Pelvis radiography anteroposterior (A) and Lowenstein (B) at 4 years. Shows the difference after Dega Osteotomy with pelvis radiography anteroposterior (C) and Lowenstein (D), after 3 years of follow up.

In order to increase coverage to prevent progression of subluxation and improve joint containment and stability, a Dega-type acetabuloplasty was performed at the age of 5 years and 10 months, we used 2 bioabsorbable pins that allowed the omission of the installation of a spica cast [11].

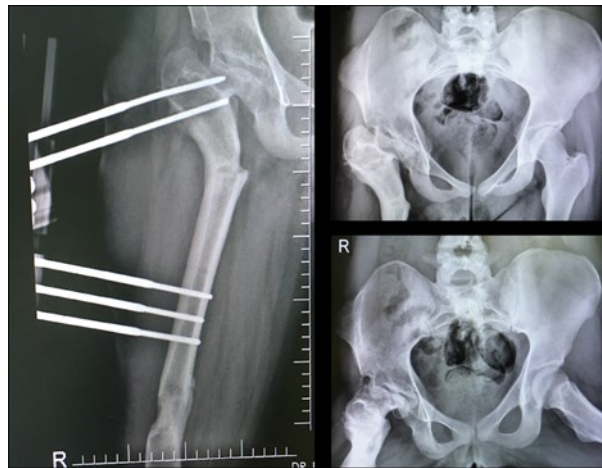
Four months after the surgery, she only showed improvement in abduction, reaching up to 20°. The radiographs show the same initial epiphyseal characteristics, but with increased acetabular coverage (Fig. 1 B and D).



**Figure 2:** Right hip MRI before Dega osteotomy.

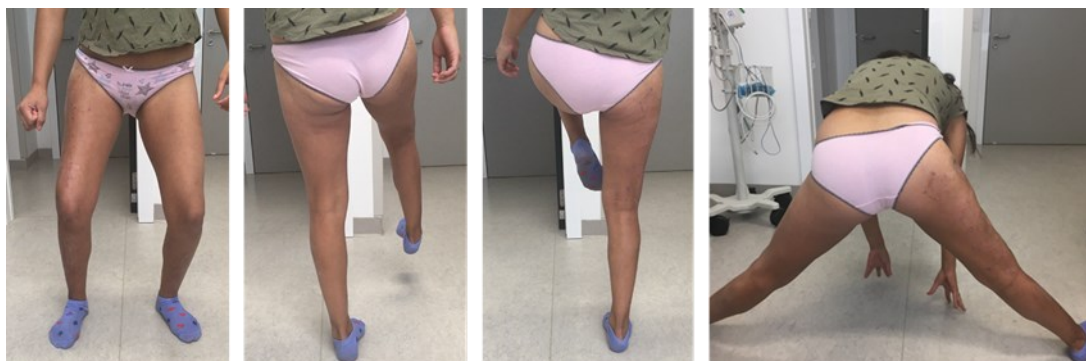She was referred to physiotherapy, managing to improve ranges of joint mobility; with abduction of 30°, internal rotation 5°, external rotation 20° and flexion 120°. She maintains a 25 mm LLD that is corrected with a 10 mm shoe enhancement. She reports no pain during moderate intensity physical activities.

Patient present similar clinical characteristics until she was 10 years old, when she lost follow up. She consulted again 5 years later due to persistent pain in the left inguinal region. At that time, her physical examination was abduction 5°, internal rotation 5°, external rotation 20°, flexion 95° and LLD of 30 mm.



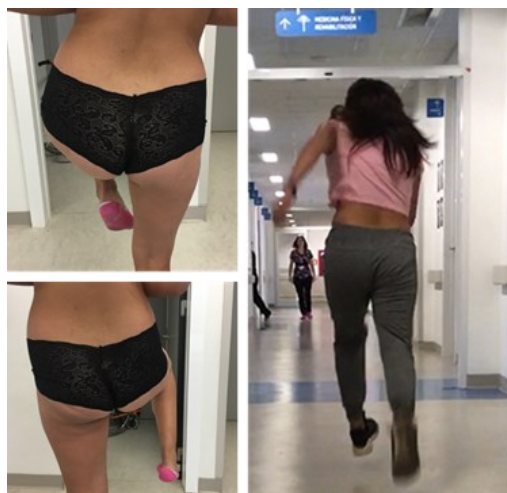**Figure 3:** Pelvic support osteotomy, with proximal valgus and distal femoral lengthening.

With these clinical and radiological evaluations, a pelvic support osteotomy was planned and performed at the age of 15 (figure 3). The fixator was removed 10 months after surgery, and her LLD was compensated. Trendelenburg and hip mobility were improved, allowing her to perform daily living activities and sports without pain (Figure 4).



**Figure 4:** Mobility after external fixator removal, removal at 15 years old.

At the moment, 8 years after pelvic support surgery (22 years old), our patient presents abduction 30°, internal rotation 10°, external rotation 20°, flexion 120, LLD of 5 mm, and delayed positive Trendelenburg sign (Figure 5).



*Figure 5: Patient at the age of 22 years old.*

## Discussion

Degenerative arthropathy of the hip has a negative impact on an active lifestyle. If left untreated, it can get progressively worse leading to eventual hip replacement at an unusual age. Hip preservation surgery focuses on helping patients postpone or even prevent the need for hip replacement in the future, orthopedic surgeons would prefer not to place hip prostheses in younger people, because the prosthesis will probably have to be replaced at least once during the patient's lifetime [12].

Delay in the diagnosis and treatment of septic arthritis of the hip can lead to a spectrum of pathological changes. Especially in the newborn, the sequelae can vary from very subtle alterations to serious damage of the proximal femur such as complete destruction of the proximal femoral epiphysis, dislocation, accompanied by leg-length discrepancy, which with stable hips varies from 2 to 5 cm, and with unstable hips can reach up to 14 cm.

Choice of treatment method will depend on the current discrepancy as well as the expected discrepancy in skeletal maturity, which encourages maintaining coverage and stability of the hip to minimize this difference. The different pelvic osteotomies for the immature skeleton such as Salter, Dega and Pemberton can help to improve joint support and stability. [7,8,9].

Any surgical treatment for severe sequelae of childhood septic arthritis of the hip should be considered as a measure that temporarily improves clinical function and delays definitive procedures that are reserved for adult patients.

The literature states that in hip reconstructions with type IV-A sequelae, it is necessary to determine with the help of imaging tools such as MRI, if there is any non-ossified epiphyseal cartilage. In patients younger than 6 years with a reasonable size of non-ossified cartilage layer over the neck remnant, repositioning of the femoral remnant in the acetabulum has been proposed. However, secondary procedures are generally needed to improve acetabular coverage and discrepancy.

When there is no reasonable cartilage layer, greater trochanter arthroplasty has been proposed. But the progressive posterior subluxation found in most patients requires additional procedures, such as femoral osteotomy, pelvic osteotomy, and acetabuloplasty, to maintain coverage and containment.

The Ilizarov hip reconstruction osteotomy, also known as pelvic support osteotomy, is unique because it simultaneously addresses hip instability and limb length discrepancy in a single operation. By combining acute angular valgus osteotomy in the proximal femur and gradual femoral lengthening in the distal femur, both problems can be treated simultaneously and the need for multiple surgical procedures can be avoided [12, 13].

Should be considered that, due to the potential for spontaneous growth and remodeling, it can't be performed under the age of 12. Taking the above into consideration, our patient is a child under 5 years old with CHOI IV type-A hip with hip subluxation and scant cartilage remnant evaluated by MRI. To preserve her hip, the decision was made to perform a Dega osteotomy to replace the greater trochanter arthroplasty to increase coverage and correct subluxation, obtaining a stable hip and improve patient's symptoms, and her IADL for 10 years after surgery.

In early adolescence, the patient consulted due to painful symptoms at the hip level and in IADL. Given the patient's age, it was decided to perform a pelvic support osteotomy, eliminating pain, allowing physical activities, adequate joint movements and delayed positive Trendelenburg sign [14].

## Conclusion

This clinical case of hip preservation reinforces the importance of maintaining hip stability with adequate coverage that does not allow proximal migration of the residual femoral component to minimize discrepancies in skeletal maturity.

On the other hand, Ilizarov hip reconstruction should be considered a promising option. This is particularly true for children close to skeletal maturity who have an altered hip caused by severe sequelae of septic arthritis in the NB period, associated with lower limb length discrepancy and Trendelenburg gait. Ilizarov hip reconstruction not only improves hip biomechanics while preserving hip motion, but also equalizes limb length discrepancies through femoral lengthening improving activities of daily living.

In conclusion, we can confirm that overall, throughout the follow-up period, our patient has shown satisfactory functional outcomes regarding range of motion, residual pain, and compensation for her leg length discrepancy, temporarily postponing the necessity for a primary hip replacement in early adulthood.

Despite the rarity of serious sequelae in septic arthritis patients, it's important to recognize the potential biomechanical alterations it can cause. Therefore, it's essential to consider multiple therapeutic and surgical options during follow-up. This case report only presents one approach to address a severe complication of septic arthritis.

## Conflict of Interest

The authors declare that they have no conflict of interest.

## Funding

The author(s) received no financial support for the research, authorship, and/or publication of this article.

## References

1. Hänel K, Andrea, Rodríguez, Pilar, Silva B., Antonia, Meza M., Gisela, & Piñera M, Cecilia. (2020). Osteoarticular infections in children: five years' experience. *Chilean Journal of Infectology*, 37(6), 742-749.
2. Zunino, Carlos, Vomero, Alejandra, Pandolfo, Soledad, Gutiérrez, Claudia, Algorta, Gabriela, Pérez, M. Catalina, & Giachetto, Gustavo. (2017). Etiology and evolution of osteo-articular infections 2009-2015: Pediatric Hospital of the Pereira Rossell Hospital Center, Uruguay. *Chilean Journal of Infectology*, 34(3), 235-242.
3. Cohen E, Katz T, Rahamim E, Bulkowstein S, Weisel Y, Leibovitz R, Fruchtmann Y, Leibovitz E. Septic arthritis in children: Updated epidemiologic, microbiologic, clinical, and therapeutic correlations. *Pediatr Neonatol*. 2020 Jun;61(3):325-330
4. Swarup I, LaValva S, Shah R, Sankar WN. Septic Arthritis of the Hip in Children: A Critical Analysis Review. *JBJs Rev*. 2020 Feb;8(2): 101-103.
5. Rutz E. Septic arthritis of the hip joint in children is an emergency. *Afr J Paediatr Surg*. 2012 Jan-Apr;9(1):1-2.
6. Hunka, L; Said, SE, and McKenzie, DA, et al: Classification and surgical management of severe sequelae of septic hips in children. *Clin Orthop*, 171: 30-36, 1982.
7. Forlin E, Milani C. Sequelae of septic arthritis of the hip in children: a new classification and a review of 41 hips. *J Pediatr Orthop*. 2008 Jul-Aug;28(5):524-8.

8. Choi IH, Pizzutillo PD, Bowen JR, Dragann R, Malhis T. Sequelae, and reconstruction after septic arthritis of the hip in infants. *J Bone Joint Surg Am.* 1990 Sep;72(8):1150-65.
9. IH, Yoo WJ, Cho TJ, Chung CY. Operative reconstruction for septic arthritis Choi of the hip. *Orthop Clin North Am.* 2006 Apr;37(2):173-83
10. Baghdadi T, Saberi S, Sobhani Eraghi A, Arabzadeh A, Mardookhpour S. Late sequelae of hip septic arthritis in children. *Acta Med Iran.* 2012;50(7):463-7.
11. Freire M., et al "Analysis of using bioabsorbable implants in orthopedic and trauma surgery in a Chilean Children's Hospital"- *Acta Scientific ORthopaedics* 6.12 (2023): 47-53.
12. Pontes MDS, Bortolin PH, Volpon JB. Double femoral osteotomy for the treatment of severe sequelae of the immature hip. *Acta Ortop Bras.* 2020 Nov-Dec;28(6):287-290.
13. Halvorsen V, Fenstad AM, Röhrli SM, Engesæter LB, Nordsletten L, Terjesen T, Furnes O, Hallan G. Hoftelidelser hos barn og unge – utredning og behandling av senfølger [Hip disorders in children and adolescents – assessment and treatment of sequelae]. *Tidsskr Nor Lægeforen.* 2020 Nov 23;140.
14. Pai V. S. (1996). Significance of the Trendelenburg test in total hip arthroplasty. Influence of lateral approaches. *The Journal of arthroplasty*, 11(2), 174–179.

**Citation:** Vergara M, Riquelme JP, Rivadeneira A, Gaggero MC. Hip Preservation in Sequelae of Septic Arthritis in the Newborn, Case Report. *SVOA Orthopaedics* 2024, 4:3, 55-60.

**Copyright:** © 2024 All rights reserved by Vergara M., et al. This is an open access article distributed under the Creative Commons Attribution License, which permits unrestricted use, distribution, and reproduction in any medium, provided the original work is properly cited.